

ABOUT DIAGNOSE OF SWINE ASCARIASIS AND THEIR RISK

Yilka (MIJA) ÇANI¹ and Bejo BIZHGA²

¹ PhD Candidate, Faculty of Veterinary Medicine, Agricultural University, Tirana, Albania

² Faculty of Veterinary Medicine, Agricultural University, Tirana, Albania

Keywords: Ascariasis, swine, prevalence, parasitic loud.

ABSTRACT

Ascariasis is a disease of all categories of pigs with zoonotic role. It is caused by the genus nematode *Ascaris* (Ascarididae). Ascariasis infests all pig farms in our country and a considerable number of pigs, whose productivity is severely compromised. Stool samples study and evaluation of epidemiological prevalence and parasitic loud infestation confirmed this in all herds of pigs involved in the study, in all the ways of breeding and the entire territory of the country. Ascariasis was observed in all categories of pigs, while the most affected category were the piglets to 7 months (about 80% prevalence, parasitic loud 164 e/g/f). Ascariasis was observed in all categories of sows (about 50%, 120 e/g/f), while only boars resulted in less infested category (about 30% and 42 e/g/f). Coproscopic examinations are effective and offer the possibility of epidemiological estimates, while post-mortem examinations in slaughterhouses are efficient alternatives, low cost and provide sufficient data for swine ascariasis. Diagnostic techniques from the nasal discharges in piglets, was very simple and efficient. As a routine technique to perform quantitative diagnosis and other parasitic estimates, this technique was implemented for the evaluation of ascariasis, especially for alive piglets. Based on the results of this study it was concluded that ascariasis infection is the most important cause of reduce of production in pigs in our country.

INTRODUCTION

Ascariasis in pigs in most cases is attributed *Ascaris suum*, because rarely happens to pigs infested by *Ascaris lumbricoides* (the human ascarids), or both together. *Ascaris suum* is known as the big ascarid of swines. *Ascaris suum* is a parasitic nematode, which causes swine ascariasis. Ascariasis is zoonosis because *Ascaris suum* also infest people (especially children and people who are in contact with pigs). *Ascaris suum* is widespread in all over the world and especially in piglets of our country. Swine ascarids might go up to 40 cm long (female). *Ascaris suum* is a representative of the family Ascarididae, and one of the most maleficent parasites in swines, especially in piglets. Its biological cycle is direct, but it might also be developed through paratenic hosts. Pigs, especially piglets are infested with L₂ through food or water. Larva through hepatic migration comes back to the liver in L₃ and by means of blood circulation it reaches the liver and goes down to the alveoli. This process is known as the phase of hepatic-tracheal migration, which by swallowing goes down to the intestines, where it settles and 2 months after infestation is transformed into a grown nematode. In pigs, *Ascaris suum* is the most common parasite in Albania with a prevalence of more than 50%. Pigs (mainly 0-3 months piglets) with ascariasis have lesions in liver and lungs, the latter causing a predisposition to viral and bacterial infections. Ascariasis is traditionally being controlled by anthelmintics as a mass therapy.

Despite the high efficacy of these products, the long-term effect of the anthelmintics is disappointing and the problem with ascariasis is actually increasing. The most important reason for this is the prodigious fecundity of *Ascaris* and the ability of eggs to survive for long periods of time in the environment. This results in a high environmental contamination

and rapid reinfection. Eggs have an elliptic form 45 up to 75µm long and a diameter 35 up to 50 µ. In the environment they are transformed into invasive larvae and they infest swines, especially piglets 0-7 months old. Reduction in the productivity of swines is the main characteristic of ascaridiosis.

The clinical signs are attributed to the number of parasites, which colonize the digestive system and cause characteristic verminous bronchopneumonia, which is especially expressed into piglets. Swines comprise one of the most important income from farming in Albania. In Central and Southern Albania swines are generally kept in intensive systems, while in the north of the country they still continue the extensive swine growth, but with a tendency to transform them into intensive economies.

MATERIAL AND METHOD

For quantitative and qualitative studies we used the stool examinations of swabs taken from the nose disargheat alive pigs. The fecal samples were taken individually in sows, pre-sows, and uncastrated pigs, while the samples in the piglets category were fecal samples of stables or padoks. The qualitative and quantitative sedimentation, the technique of swimming with the salt was the coproscopic method used in the study. To evaluate the parasitic load we applied the Mc Master technique. The samples were taken 50 gr for the individual samples and 150 gr for the collective ones. They were transported and preserved in containers and were generally examined within 24 hours. In cases when conservation was necessary they were kept in refrigerator at 4 degrees C (Coates, S., 2000). For examination of nasal tampons in piglets were taken and examined within 12 hours at stereomicroscopes. For each tampon was counted the number of invasive larvae.

Post mortum examinations to the slaughterhouse were alternative methods of study for post mortem animals. Livers were checked for the presence of liver milk spots. All samples (adult parasites, larvae, organs) were preserved in 70 % ethanol. The content of the broncopulmonaty system and small intestines of the animals were collected and was washed to collect any adult and remaining larvae. We collected and washed all ascarids in the small intestine (Roepstor , A. 2003). Within 2 hours after necropsy of the pigs, the L4 and L5 were collected, were measured, counted and differentiated by sex. Livers from pigs were examined for superficial liver white spots which were classified as being either of the di use granulation-tissue type or the lymphonodular type (Slotved, H.C., at. al. 1997). In piglets we examined leaks nasal for the presence of invasive larvae. The washing was added to the corresponding content. The content plus washing was passed through a sieve and *A. suum* larvae were counted under a microscope. This method es the alive piglets were applied in testing and comparative level and as alternative methods of coproscopic examination especially in piglets in slaughterhouse (Roepstor , A. (2003). Alternative methods of diagnosis will extend to the entire territory of the country. In pigs, from fecal samples were taken and especially in young piglets we became especially careful with clinical observation for signs of pneumonia and when no nose leaks were examined for the presence of larvae.

RESULTS AND DISCUSSIONS

The results of the coproscopic observations for the presence and evaluation of parasitic load by *Ascaris suum* are presented detailed according all swine categories. Summary include coproscopic examinations average scores for all categories of pigs on all breeding systems in the whole territory of the country.

Table 1

Results of coproscopic examinations.

Nr	Age group	Samples (no)	Infestation level no/%	Parasitic loads n/e/g/f	The average parasitic loads	The average live weight kg
1	Piglets 0-3 months	120	108/90%	60-1200	142	18,7
2	Piglets 3-7 months	224	161/71.87%	50-1800	184	39,3
3	Sows to be substituted	163	78/47.85%	70-620	140	86,7
4	Sows before farrowing	78	34/43.58 %	40-1200	122	91,1
5	Lactating sows	126	61/48.4%	80-760	134	89,6
6	Boars	27	8/29.62 %	20-260	42	118.4

The results show clearly that *Ascaris suum* is really frequent among swines in our country. It resulted to be present in all over the territory with considerable variations among swine categories, in different geographical regions and in different systems of breeding. There are regional variations which are often attributed to the hygienic sanitary conditions in stables and the efficiency of executing the dehelminth schemes. In the economies of intensive growth the highest result appeared in the south and north Albania with a prevalence of 84 %. While in the other economies the lowest level of the region was in middle Albania with 18 %. In intensive economies, excluding the category of uncastrated pigs there is a considerable level of *Ascaris suum*. However the riskiest category are piglets 3-7 months old where parasitic load varies about 184 v/g/f. Almost the category of the sows to be substituted represents one category with piglets (over 7 months old) gives evidence for an increasing tendency on the parasitic load. This increase goes up to 20 %. In sows before farrow there is a parasitic load of about 122 v/g/f (minimum 40-maximum 1200) and this is one of the main reasons of piglet infestation source in stables. The parasitic load for lactation sows resulted 134 v/g/f (minimum 80-maximum 760). We notice a high parasitic load for lactation sows and this explains with the decrease of their condition during lactation and the lack of veterinary and breeding care for this category.

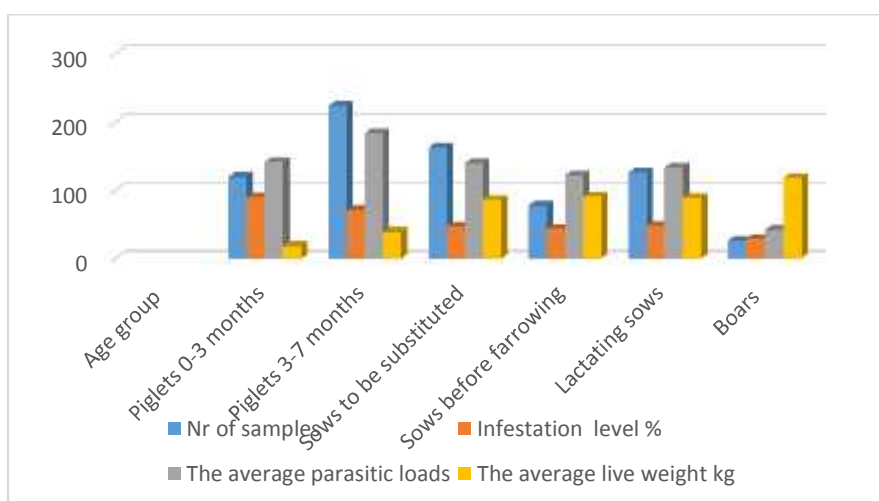


Fig.1. The values of coproscopic examinations.

The coproscopic examinations showed that *Ascaris suum* is really problematic for all economies of extensive and intensive growth of swineries. Prevalence in the economies of ½ in middle intensive growth (Tirana, Lac untill Lezhe) and North west Albania (Shkodra) resulted respectively 84 and 84 %. The highest parasitic load and a prevalence of the level above 90 % in the economies of extensive growth, which is still in the level of households severely damages swine productivity. In the north and northeast regions of Albania, swine breeding system still remains a family tradition, at an empiric level where the main food for swines is the refuse of the family, almost completely without profilactic and medication precautions. In some cases the parasitic load is scary; there have often been found over 1200 v/g/f. In almost all the household economies no dehelminth is applied to sows before farrow.

We did macroscopic observations and sampled the whole digestive apparatus, hepar, lungs and broncioles. The small intestine was cut and open, washed in saline, and faeces and the mucus scraped in microscope. Large *A. suum* were removed before the intestinal contents and the mucus mixture were processed according to the agar-gel technique described by Slotved et al. (1997), modified by incubating the agar-gels for 3 h. For all tracer pigs the entire mixture of contents and mucus was processed. At the slaughter, the lungs and broncioles were observed for signs of pneumonia and ascarids larvae were colected and examined. All samples were preserved in 70 % ethanol. Intestinal worms were for each pig were colected and measured. Livers from pigs were examined for superficial liver white spots which were classified as being either of the di use granulation-tissue type or the lymphonodular type (Slotved et al. 1997). Coproscopic examinations showed that imported swines resulted to be positive for *Ascaris suum*. We think that the reason is related to non fulfillment of dehelminth scheme for swines from the economies that import them to our country.

Table 2

Results of alternative diagnosis.

Nr.	Age group	Samples (no)	Verminose broncopneumonia no/%	Ascarids in intestine no/%	Ascarids in intestine. Variation and average parasitic loads	Lung spots no/%	Pigs with larvae in nasal sputum no/%
1	Piglets 0-3 months	52	18/34.6	22/42.3	1-40/14	42/80.76	14/26.92
2	Piglets 3-7 months	134	42/31.3	68/50.74	1-22/8	8/7.53	17/12.68
3	Sows to be substituted	24	2/8.33	9/37.5	1-14/6	0/0	0/0
4	Sows before farrowing	8	0/0	3/37.5	1-16/8	0/0	0/0
5	Boars	6	0/0	1/16.66	8/8	0/0	0/0
6	Total	224	62/27.67	103/45.98	1-40/7	50/22.32	31/13.84

The post mortum diagnosis was done for 224 pigs. From samples we examined macroscopically the content of the intestines and counted L₅ of *Ascaris sum*. 46 % of the samples resulted positive for *Ascaris suum* in intestines. In 4 samples almost 10 % of them counted up to 40 *Ascaris suum* grown within the intestine.

In total examinations, signs of pneumonia was observed in 62 pigs or 27.67%. The highest level of infestation was at piglets 3-7 months, where present signs of pneumonia about 50% of the examined piglets. Lesions of interstitial pneumonia correlated to the number of eggs ingested and time of infestation. Thus, they are numerous as the number of eggs ingested by animals is great and finally invasion occurred. In such cases, the patients manifests respiratory symptoms (cough and dyspnoea) with petechiae or hemorrhage and accumulation of eosinophils roll larvae. These manifestations are more pronounced when infections are mixed. Hepato-phase migration is very maleficent in piglets. Larvae stage II pierce intestines and enter the blood vessels (veins), beginning their migration to the liver, where they stay 4-5 days and transformed into L₃ larvae that have come to pass hepatic liver intravenous in v.cava caudalis and the right half of the heart, from which through the pulmonary artery into the lungs reach 4-7 days after infestation (Carstensen, L., Vaarst, M. and Roepstor , A. 2002). Pierce blood vessels and walls of the alveoli, come in alveoli and begin to climb in the airways, continuing the movement and supported by the device mukociliar, larvae emerge in the pharynx where together with saliva and fluids bronchial swallowed and down to the casing begins intestinal phases.

Lung spots were noted in a limited number of pigs. In total around 23% of pigs were noted signs of migration in the liver. Pigs 0-3 months resulted typically with lung spots, where 81% of them in the liver presented signs of migration (Masure D., at. al. 2013). Piglets 3-7 months resulted in less lung spots (about 13%), while there not noted in other categories of pigs.

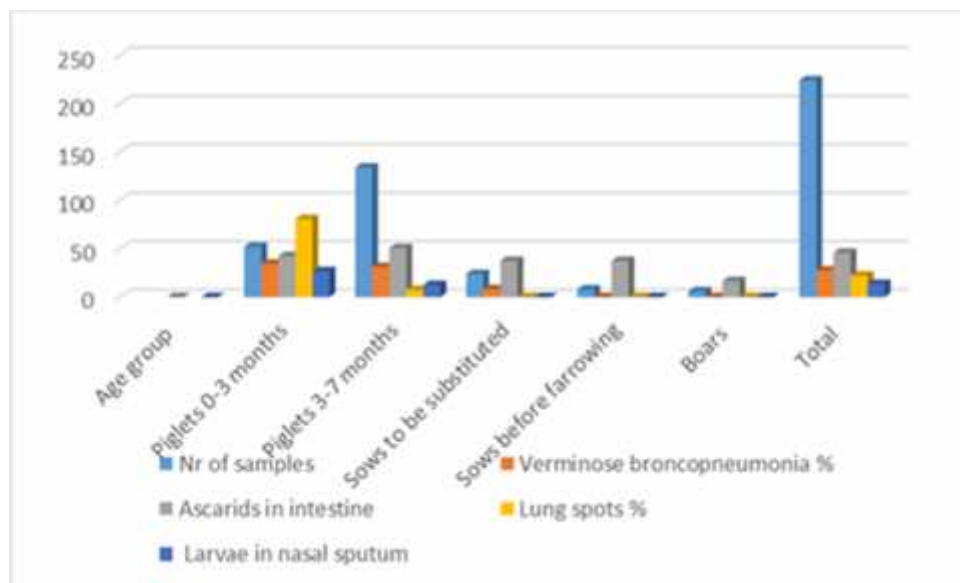


Fig.2. The values of coproscopic examinations.

In category of piglets up to 3 months we examined samples of runny nose and resulted positive for the presence of larvae 27% of them. Among those, we sampled with tampons in their noses and prepared to microscopic swabs. Tampon discharge were observed as wet and dry preparations. In these were found migrating larvae of *A. suum*. Larvae in the nose and mouth to bowel swallowed or come with sneezing or runny nose in the external environment. All samples tested positive for migratory larvae of *A. suum*. Diagnostic techniques proved to be very simple, extremely efficient and very fruitful for the outcome (Mejer, H., at. al. 2000). Work is underway to convert into quantitative techniques to evaluate and estimate the number of larvae and other parasites. With this technique, migrating larvae were found in about 13% of piglets at 3-7 months, while other categories resulted clean. *A. suum* life lasts about 1 year. *A. suum* exists everywhere where pigs

grow and the level of routine infestation varies between 20-90%, depending on the specific conditions. *A. suum* infest all ages of pigs, but heavy infestation is more present on age 1-5 months.

CONCLUSIONS

Ascaris suum infection is present in all the swine categories and all over the territory of the country. The results showed that the most affected category are pigs 0-3 months with 90% of heads and average parasitic load 142 e/g/f. In the category 3-7 months prevalence resulted in 71.9% and average parasitic load 184 e/g/f. Category sows to be substituted resulted in a prevalence of 47.85% and average parasitic load 140 e/g/f. Category sows before farrow resulted in a prevalence of 43.58% and average parasitic load 122 e/g/f. Category lactating sows resulted in a prevalence rate of 48.4% and average parasitic load 134 e/g/f. Boars resulted in less infested category with 29.62% and average parasitic load 42 e/g/f. Coproscopy examinations are efficient and offer the possibility of epidemiological estimates, while post-mortem examinations in slaughterhouses are efficient, low cost and provide sufficient data for *Ascaris suum* infection. Post mortem examinations to the slaughterhouse were alternative methods of study. In piglets up to three months we examined nasal secretions for the presence and number of larvae. This method used as routine techniques to perform quantitative diagnosis and other parasitic *Ascaris suum* infection estimates.

Ascaris suum is currently the helminth highly prevalent in pigs, resulting in significant economic losses. In the pig industry, this parasitic disease is controlled by mass treatment of the pig herd with anthelmintics. However, due to the subclinical nature of the disease combined with the lack of appropriate diagnostic tools, ascariasis often remains undiagnosed, creating a lack of information regarding the worm-status of a farm. This makes it difficult to evaluate the currently applied deworming programs and the possible economical losses caused by the presence of this parasite on the farm.

BIBLIOGRAPHY

1. **Carstensen, L., Vaarst, M. and Roepstor , A.** 2002 - *Helminth infections in Danish organic swine herds*. Veterinary Parasitology 106, 253–264.
2. **Coates, S.**, 2000 - *Modelling the population dynamics of Ascaris suum in pigs*. Ph.D. thesis, Danish Centre for Experimental Parasitology, Copenhagen, Denmark and the University of Warwick, Coventry, UK.
3. **Masure D., Vlaminc J., Wang T., Chiers K., Van den Broeck W., Vercruysse J., Geldhof P.**, 2013 - *A role for eosinophils in the intestinal immunity against infective Ascaris suum larvae*. Plos Neglected Tropical Diseases 7(3):e2138 (IF 4,716).
4. **Mejer, H., Wendt, S., Thomsen, L. E., Roepstor , A. and Hindsbo, O.**, 2000 - *Nose-rings and transmission of helminth parasites in outdoor pigs*. Acta Veterinaria Scandinavica 41, 153–165.
5. **Napravnik J., Berka T.**, 2002 - *Cause and effect of ascariasis in pig herds*. Helminthologia, 39: 171-183.
6. **Nejsun P., Parker E.D. Jr., Frydenberg J., Roepstorff A., Boes J., Haque R., Astrup I., Prag J., Sorensen U.B.S.**, 2005 - *Ascariasis is a zoonosis in Denmark*. J Clin Microbiol, 43(3): 1142-1148.
7. **Ngowi H.A., Kassuku A.A., Maeda G.E., Boa M.E., Willingham A.L.**, 2004 - *A slaughter slab survey for extra-intestinal porcine helminth infections in northern Tanzania*. Trop Anim Health Prod, 36:335-340.

8. **Nsoso S.J., Mosala K.P., Ndebele R.T., Ramabu S.S.**, 2000. The prevalence of internal and external parasites in pigs of different ages and sexes in Southeast District, Bostwana. *Onderstepoort J Vet Res*, 67: 217-220.
9. **Roepstor , A. and Nansen, P.**,1994 -*Epidemiology and control of helminth infections in pigs under intensive and non-intensive production systems*. *Veterinary Parasitology* 54, 69–85.
10. **Roepstor , A.**, 2003. *Ascaris suum in pigs : population biology and epidemiology*. Doctorate thesis, the Royal Veterinary and Agricultural University, Copenhagen, Denmark.
11. **Sakakibara A, Baba K, Niwa S, Yagi T, Wakayama H, Yo-shida K, Kobayashi T, Yokoi T, Hara K, Itoh M, Kimura E**, 2002. *Visceral larva migrans due to Ascaris suum which pre-sented with eosinophilic pneumonia and multiple intra-hepatic lesions with severe eosinophil infiltration-outbreak in a Japanese area other than Kyushu*. *Intern Med*, 1: 574-579.
12. **Slotved, H.C., Barnes, E. H., Eriksen, L., Roepstor , A., Nansen, P. and Bjorn, H.**, 1997 - *Use of an agar-gel technique for large-scale application to recover Ascaris suum larvae from intestinal contents of pigs*. *Acta Veterinaria Scandinavica* 38, 207–212.
13. **Vlaminck J., Düsseldorf S., Heres L., Geldhof P.**, 2015 - *Serological examination of fattening pigs reveals associations between Ascaris suum, lung pathogens and technical performance parameters*. *Veterinary Parasitology* 210:151-158
14. **Vlaminck J., Nejsun P., Vangroenweghe F., Thamsborg S., Vercruysse J., Geldhof P.**, 2012 - *Evaluation of a serodiagnostic test using Ascaris suum haemoglobin for the detection of roundworm infestation in pigs*. *Veterinary Parasitology* 189:267-273.
15. **Wang T., Van Steendam K., Dhaenens M., Vlaminck J., Deforce D., Jex A.R., Gasser R.B., Geldhof P.**, 2013 - *Proteomic analysis of the excretory-secretory products from larval stages of Ascaris suum reveals high abundance of glycosyl hydrolases*. *PLoS Neglected Tropical Diseases* 7(10):e2467.
16. **Weng YB, Hu YJ, Li Y, Li BS, Lin RQ, Xie DH, Gasser RB, Zhu XQ**, 2005. *Survey of intestinal parasites in pigs from inten-sive farms in Guandong province, Peoples Republic of China*. *Vet Parasitol*, 127(3-4): 333-336.